



## **DISTRICT NINE MEDICAL EXAMINER'S OFFICE**

**Jan C. Garavaglia, M.D., *Chief Medical Examiner***  
**Gary Lee Utz, M.D., *Deputy Chief Medical Examiner***  
**Marie H. Hansen, M.D., *Associate Medical Examiner***  
**Joshua D. Stephany, M.D., *Associate Medical Examiner***  
**Sara H. Zydowicz, D.O., *Associate Medical Examiner***

---

**Re: Florida Statute, Chapter 119, Public Records Laws Exemption**

Please be advised that the District Nine Medical Examiner's Office is an office under Orange County Government. As such, our records are open for personal inspection and copying by any person. On occasion; however, there are certain pieces of information in our records that might have to be redacted due to a Florida State Statute exemption. The record you have requested does have such an exemption. Therefore, please be advised that the redacted information is based on the following Florida State Statute, 119.071(2)(d) and 119.071(4)(c), which exempts from public record the identity of law enforcement surveillance and undercover personnel.

**OFFICE OF THE MEDICAL EXAMINER  
DISTRICT NINE  
2350 E. Michigan Street  
Orlando, Florida 32806-4939**

**REPORT OF AUTOPSY**

**DECEDENT:** Ibragim Todashev      **CASE NUMBER:** ME 2013-000623

**MANNER OF DEATH:** Homicide      **IDENTIFIED BY:**

**AGE:** 27 years

**SEX:** Male

**RACE:** White

**DATE OF DEATH:** 5/22/2013

---

**DATE/TIME OF AUTOPSY:** May 22, 2013 at 11:00 am

**PERFORMED BY:**

*Gary Lee Utz* 7/8/2013  
Gary Lee Utz, MD, Deputy Chief Medical Examiner

---

**CAUSE OF DEATH:** Multiple gunshot wounds

---

**AUTOPSY FINDINGS**

- I. Gunshot wound of head (Gunshot Wound "A"), indeterminate range, entering left parietal scalp, without exit:
  - A. Perforation of skull and brain
  - B. Subarachnoid hemorrhage
  - C. Calvarial fractures
  - D. Basilar skull fractures
  - E. Projectile recovered from soft tissue at left base of skull
  
- II. Gunshot wound of torso (Gunshot Wound "B"), indeterminate range, entering left upper back, without exit:
  - A. Perforation of lung
  - B. Hemothorax
  - C. Rib fracture
  - D. Projectile recovered from left lung

continued...

- III. Gunshot wound of torso (Gunshot Wound "C"), indeterminate range, entering right upper back, without exit:
  - A. Perforation of lung
  - B. Hemothorax
  - C. Rib fractures
  - D. Projectile recovered from right chest wall
  
- IV. Gunshot wound of torso (Gunshot Wound "D"), indeterminate range, entering right back, with exit:
  - A. Perforation of right lower lung lobe
  - B. Rib fracture
  - C. Hemothorax
  - D. Exit wound right lower chest
  
- V. Gunshot wound of torso (Gunshot Wound "E"), indeterminate range, entering left chest, without exit:
  - A. Perforation of heart
  - B. Perforation of aorta
  - C. Perforation of esophagus
  - D. Hemothorax
  - E. Hemopericardium
  - F. Projectile recovered from subcutaneous tissue of right lower back
  
- VI. Gunshot wound of torso (Gunshot Wound "F"), indeterminate range, entering left upper arm, without exit:
  - A. Exit wound medial left upper arm
  - B. Reentry wound left chest
  - C. Perforation of heart
  - D. Rib fracture
  - E. Projectile recovered from heart
  
- VII. Gunshot wound of torso (Gunshot Wound "G"), indeterminate range, entering left upper arm, without exit:
  - A. Exit wound medial left upper arm
  - B. Reentry wound left chest
  - C. Perforation of costal cartilage
  - D. Perforation of stomach
  - E. Projectile retrieved from stomach

TODASHEV, IBRAGIM  
ME 2013-000623  
PAGE 3

**TOXICOLOGY ANALYSIS:** See laboratory report.

**CONCLUSION:** In consideration of the circumstances surrounding the death, and after examination of the body, and review of the available investigative records, it is my opinion that the death of Ibragim Todashev, a 27 year old white man who was shot by a Federal Bureau of Investigation agent, is due to multiple gunshot wounds. The deceased suffered at total of 7 gunshot wounds. One projectile entered the top of the head, passed through the brain and the base of the skull. It was recovered. Three projectiles entered the back; one exited and two were recovered in the body. Two projectiles passed through the left upper arm and re-entered the left chest. An additional projectile also entered the left chest. All three projectiles were recovered. There is no evidence of close range firing in any of the gunshot wounds.

The manner of death is homicide.

## **POSTMORTEM EXAMINATION OF THE BODY OF IBRAGIM TODASHEV**

A postmortem examination of the body of a white man identified as Ibragim Todashev is performed pursuant to Florida statute 406.11 by Gary Lee Utz, MD, Deputy Chief Medical Examiner, District Nine at the Orange County Medical Examiner facility, Orlando, Florida on 5/22/2013 at 11:00 am.

**IDENTIFICATION:** The body of Ibragim Todashev is identified by  
The positive visual identification is made to  
on 5/21/2013 at 7:13 pm at the scene.

**CLOTHING AND VALUABLES:** The body is received clad in a T-shirt, jeans with a web belt, boxer briefs, and olive socks. The hands and feet are bagged. A key fob and a lighter are present in the left front pants pocket. Three keys are on the ring. There are defects on the front of the T-shirt consistent with the entrance wounds later described. The most medial defect is  $\frac{3}{4}$  inch x  $\frac{1}{2}$  inch. The middle defect is round,  $\frac{3}{8}$  inch in diameter. The most lateral defect is a cluster of small, apparently individual defects, measuring in total  $1\frac{1}{2}$  inches x  $\frac{1}{2}$  inch. On the back of the T-shirt are three roughly circular defects corresponding in location to the gunshot entrance wounds later described. In the right left lower front are multiple small defects measuring  $\frac{1}{8}$  to  $\frac{1}{4}$  inch that roughly correspond to the location of the exit wound in the right lower chest. There are multiple cosmetic defects in the jeans which are not associated with gunshots. None of the defects display evidence of close range firing.

**SPECIAL PROCEDURES:** Prior to the performance of the autopsy postmortem radiographs were obtained. Five projectiles were identified in the torso, and one in the head.

Fingernail clippings were obtained.

### **EXTERNAL EXAMINATION**

The body is that of a well-developed, well-nourished, white man that weighs 159 pounds, measures 68 inches in length, and appears compatible with the stated age of 27 years. The body is cool to touch. Rigor mortis is fully fixed in the extremities and jaw. Minimal blanching purple livor mortis extends over the posterior surface of the body, except in the areas exposed to pressure.

The scalp hair is dark brown and measures 3 inches in length over the crown. The facial hair is a closely trimmed beard and mustache. The irides are brown; the corneas are clear. The sclerae and conjunctivae are pale. There is marked bony deformity of the nose. Both ears display cauliflower type deformities. The nose and ears are without evidence of acute trauma. The oral cavity is free of blood and the mucosae are without evidence of trauma. The teeth are natural and in fair repair. The neck is without masses, and the larynx is in the midline. The thorax is well-developed and symmetrical.

The abdomen is flat. The external genitalia are those of a normal adult man.

The anus and back are unremarkable. The upper and lower extremities are well-developed and symmetrical, without absence of digits.

**IDENTIFYING MARKS AND SCARS:** A faint, linear scar oriented in the coronal plane, is present on the undersurface of the chin. There is a faint, discontinuous linear scar over the anterior aspect of the right knee.

**EVIDENCE OF MEDICAL INTERVENTION:** None.

### **EVIDENCE OF INJURY**

**NOTE:** Gunshot wounds are numbered and labeled arbitrarily.

#### **Head and Neck:**

Gunshot wound "A": A gunshot wound of entrance is identified in the left posterior parietal scalp, centered 4 ½ inches above and 1 inch posterior to the level of left external auditory meatus. It is also 1 inch below the top of the head. The wound is stellate, 5/8 of an inch x 3/8 of an inch, with a central circular punched out defect measuring slightly more than ¼ inch in diameter. There is minimal marginal abrasion. No soot or stippling is present.

The projectile travels downward, slightly toward the right, and slightly toward the rear.

The projectile enters the cranial vault producing an inwardly beveled irregular defect in the left parietal calvarium. The projectile then perforates the left

parietal lobe, perforates the left temporal lobe, perforates the left lobe of the cerebellum, and exits the basilar skull in the posterior fossa just posterior to and 1 inch lateral to the level of the foramen magnum. A damaged, partially jacketed lead projectile is retrieved from the soft tissue just deep to the skull defect and retained, labeled "Projectile from Left Base of Skull".

A  $\frac{3}{4}$  inch abrasion/pressure mark is at the lateral canthus of the left eye.

### **Torso:**

**Gunshot wound "B":** A gunshot wound of entrance (#9 in photographs) is identified in the left upper back, centered 2  $\frac{1}{2}$  inches left of the midline and 10  $\frac{1}{2}$  inches below the top of the head. The wound is round,  $\frac{3}{8}$  inch in diameter, with circumferential marginal abrasion most prominent in the 8 o'clock to 1 o'clock position. No soot or stippling is present.

The projectile travels left to right, back to front, and downward.

The projectile traverses the soft tissues of the left upper back, enters the thoracic cavity through the third intercostal space posteriorly, grazes the body of the fourth thoracic vertebra, and comes to rest in the lung. A damaged, partially jacketed lead projectile is retrieved from the upper portion of the left lower lung lobe, and retained labeled "Left Lower Lung Lobe".

**Gunshot wound "C":** A gunshot wound of entrance (#10 in photographs) is identified in the right upper back centered 2 inches to the left of the midline, and 13  $\frac{1}{2}$  inches below the top of the head. The wound is round,  $\frac{3}{8}$  inch in diameter with circumferential marginal abrasion. No soot or stippling is present.

The projectile travels left to right, back to front, and downward.

The projectile enters the right thoracic cavity at the second intercostal space near the spine, producing a comminuted fracture of the third rib. The projectile then perforates the right upper lung lobe and exits the thoracic cavity through the second intercostal space laterally. A damaged, partially jacketed lead projectile is retrieved from the soft tissue of the lateral right chest, and retained labeled "RT Chest Wall".

Gunshot wound "D": A gunshot wound of entrance (#11 in photographs) is identified in the right back centered 1 ¼ inches to the right of the midline, and 16 ½ inches below the top of the head. The wound is round, 3/8 inch in diameter, with circumferential marginal abrasion. No soot or stippling is present.

The projectile travels left to right, back to front, and downward.

The projectile enters the right thoracic cavity through the 6<sup>th</sup> intercostal space near the spine, producing a comminuted fracture of the 7<sup>th</sup> rib. The projectile then perforates the right lower lung lobe and exits the thorax through the 6<sup>th</sup> intercostal space anteriorly, fracturing the 7<sup>th</sup> rib.

A gunshot wound of exit (#1 in photographs) is identified in the right lower chest, 5 inches to the right of midline and 22 inches below the top of the head. The wound is "L" shaped, ¾ x ¼ inch, without soot, stippling, or marginal abrasion. No projectile is recovered.

Gunshot wound "E": A gunshot wound of entrance (#3 in photographs) is identified in the left lateral chest, approximately 1 inch below the level of the nipple, 6 inches to the left of midline, and 18 inches below the top of the head. The wound is oval, 5/8 x ¼ inch, with minimal circumferential marginal abrasion. No soot or stippling is present.

The projectile travels left to right, front to back, and downward.

The projectile enters the left thoracic cavity, through the fifth intercostal space producing a comminuted fracture of the fifth rib. The projectile then perforates the inferior left ventricle of the heart, perforates the aorta, grazes the esophagus, then perforates the right lower lung lobe and exits the thorax through the posterior 10<sup>th</sup> intercostal space. A damaged, partially jacketed lead projectile is retrieved from the subcutaneous tissue of the right lower back, 5 inches to the right of the midline and 21 inches below the top of the head. It is retained labeled "RT BACK".

Gunshot wound "F": Gunshot wound "F" is composed of an entrance in the left upper arm, an exit in the medial left upper arm, and a reentry wound in the torso.

A gunshot wound of entrance (#6 in photographs) is identified in the lateral left upper arms, centered 14 ½ inches below the top of the head. The wound is



round, 3/8 inch in diameter with circumferential marginal abrasion most prominent at the superior margin. No soot or stippling is present. The projectile travels left to right, front to back, and downward.

The projectile traverses the soft tissue of the left upper arm, and exits medially.

A gunshot wound of exit (#8 in photographs) is identified in the medial left upper arm, centered 18 ½ inches below the top of the head. The wound is irregular, 1 inch x ¾ inch with ragged, partially abraded margins. No soot or stippling is present. The projectile reenters the body in the left chest. A gunshot wound of entrance (#4 in photographs) is identified in the left chest in the anterior axillary line approximately 1 inch below the level of the left nipple, 8 ½ inches to the left of midline, and 18 inches below the top of the head. The wound is irregular, ¼ x ½ inch with irregular superficial abrasion at the margins measuring up to ¼ inch in thickness.

The projectile enters the left thoracic cavity through the 7<sup>th</sup> intercostal space, fracturing the 6<sup>th</sup> rib. The projectile then perforates the left lower lung lobe, perforates the lateral left ventricle of the heart, and comes to rest. A damaged, partially jacketed lead projectile is retrieved from the heart muscle, and retained labeled "Heart".

Gunshot wound "G": Gunshot wound "G", like gunshot wound "F", is composed of an entrance and exit in the left upper arm, and a reentry wound in the torso.

A gunshot wound of entrance (#5 in photographs) is identified in the left upper arm centered 17 inches below the top of the head. The wound is oval, ½ x ¼ inch with circumferential marginal abrasion, most prominent in the 12 o'clock to 2 o'clock position. No soot or stippling is present.

The projectile travels from left to right, front to back, and downward.

The projectile traverses the soft tissue of the left upper arm and exits medially. A gunshot wound of exit is identified in the medial left upper arm (#7 in photographs), 19 ½ inches below the top of the head. The wound is oval, 1 ¼ inches x 5/8 inches with scalloped, minimally abraded margins. Irregular, purplish contusions surrounds the inferior and anterior margin. Small, discrete, irregular superficial abrasions are above and below the wound. No soot or stippling is present.

The projectile reenters the body at the anterior torso. A gunshot wound of entrance (#2 in photographs) is identified in the left chest approximately 2 ½ inches below the level of the left nipple, 4 inches to the left of the midline, and 19 ½ inches below the top of the head. The wound is irregular, ½ x 5/8 inch with eccentric, irregular 5/8 inch abrasion at the superior margin. The wound edges are slightly scalloped and minimally abraded. No soot or stippling is present.

The projectile enters the subcutaneous tissue of the left chest at an oblique angle, traverses the soft tissue, and enters the body through the costal cartilage of the left 8<sup>th</sup> rib. The projectile then perforates the anterior wall of the stomach and comes to rest. A damaged, partially jacketed lead projectile is retrieved from the stomach and retained, labeled "Projectile from Stomach".

**Upper and Lower Extremities:** See above.

### **INTERNAL EXAMINATION**

**BODY CAVITIES:** The numbering of the gunshot wounds in this report, and the labeling of the gunshot wounds in photographs is completely arbitrary, and is in no way associated with the sequence in which the wounds were sustained.

Associated with the above injuries is a large defect in the anterior and lateral wall of the left ventricle of the heart. It measures approximately 8 x 4 cm. A smaller, 1.5 x 2 cm defect is present in the posterior aspect of the left ventricle at the lateral margin. Defects in the pulmonary parenchyma associated with the path of the projectiles result in minimal associated hemorrhage. Approximately 100 ml of minimally clotted blood is present within the pericardial sac, 350 ml in the left chest, and 200 ml in the right chest. No blood is present within the abdomen.

Associated with the gunshot wound of the head is thin subarachnoid hemorrhage over both convexities and the basilar brain. There is disruption of the parenchyma associated with the path of the projectile. Displaced linear fractures extend from the entry defect anteriorly and posteriorly through the calvarium. There is moderate associated subgaleal hemorrhage. Slightly displaced fractures extend into the left middle cranial fossa. There are slightly displaced fractures at the posterior margin of the exit defect in the left posterior fossa. A non

displaced linear fracture extends through the petrous portion of the left temporal bone.

The above injuries, having been mentioned once, will not be repeated in the individual descriptions of the organ systems. Those descriptions refer to the uninjured portions of the organs only.

**CARDIOVASCULAR SYSTEM:** The heart weighs 300 grams. The pericardial surfaces are disrupted owing to the gunshot wound previously described. The coronary arteries arise normally, follow the usual distribution, and are widely patent, without atherosclerosis or thrombosis. The chambers and valves exhibit the usual size-position relationships and are unremarkable; the atrial and ventricular septa are intact. The myocardium is red-brown and firm, without focal abnormalities. The aorta and its major branches arise normally, follow the usual courses, and are widely patent, without atherosclerosis. The vena cava and its tributaries return to the heart in the usual distribution and are free of thrombi.

**RESPIRATORY SYSTEM:** The right and left lungs weigh 320 grams and 300 grams, respectively. The upper airway is clear of debris and foreign material; the mucosa is yellow-tan and smooth. The pleural surfaces are smooth, glistening and, except as noted otherwise, intact. The pulmonary parenchyma displays evidence of the previously described gunshot wounds. Surrounding parenchyma is mildly hemorrhagic. Uninvolved parenchyma exudes a moderate amount of blood and frothy fluid and is without focal lesions. The pulmonary vasculature is unremarkable.

**HEPATOBIILIARY SYSTEM:** The liver weighs 1520 grams. The hepatic capsule is smooth, glistening and intact, covering a red-brown parenchyma without focal lesions noted. The gallbladder contains approximately 5 milliliters of dark green, slightly mucoid bile; the mucosa is velvety and unremarkable. The extrahepatic biliary tree is patent, without evidence of calculi.

**ENDOCRINE SYSTEM:** The pituitary, thyroid and adrenal glands are unremarkable. The pancreas has the usual yellow-tan, lobulated appearance and the ducts are clear.

**DIGESTIVE SYSTEM:** The esophagus is lined by a gray-white, smooth mucosa. The gastric mucosa is arranged in the usual rugal folds and the lumen contains a scant quantity of thin, tan liquid. The small and large intestines are unremarkable. The appendix is present.

**GENITOURINARY SYSTEM:** The right and left kidneys weigh 110 grams and 120 grams, respectively. The renal capsules are smooth, thin and semitransparent, and strip with ease from the underlying smooth, red-brown, firm, cortical surfaces. The cortices are sharply delineated from the medullary pyramids, which are red-purple to tan and unremarkable. The calyces, pelves and ureters are unremarkable. The urinary bladder contains no urine; the mucosa is gray-tan and smooth.

The prostate gland and seminal vesicles are unremarkable.

**RETICULOENDOTHELIAL SYSTEM:** The spleen weighs 100 grams and has a smooth intact capsule covering a deep red-purple, moderately firm parenchyma; the lymphoid follicles are unremarkable. The regional lymph nodes appear normal. The exposed bone marrow is red-purple and homogeneous, without focal abnormalities.

**MUSCULOSKELETAL SYSTEM:** Except as noted otherwise, the bony framework, supporting musculature, and soft tissues are not unusual.

**NECK:** Examination of the soft tissues of the neck, including strap muscles, thyroid gland, and large vessels, reveals no abnormalities. The hyoid bone and larynx are intact.

**HEAD AND CENTRAL NERVOUS SYSTEM:** The brain weighs 1370 grams. There is disruption of the dura associated with the gunshot wound previously described. Subarachnoid hemorrhage is present. The cerebral hemispheres appear to have been symmetrical. The structures at the base of the brain, including the cranial nerves and blood vessels, are intact and free of additional abnormalities. Coronal sections through the cerebral hemispheres reveal the path of the projectile but no lesions within the cortex, subcortical white matter, or deep parenchyma of either hemisphere. The ventricles are normal in caliber. Sections through the brainstem and cerebellum reveal no additional abnormalities.

TODASHEV, IBRAGIM  
ME 2013-000623  
PAGE 12

**LABORATORY EXAMINATIONS:**

Laboratory examinations were ordered and the results attached.

GLU/crg  
attachment

**Patient: TODASHEV, IBRAGIM**  
**Client Patient ID: 9-13-623**  
**Physician: UTZ, GARY**
**Age: 27 Sex: M**  
**Account#: VX23778**  
**Client: DIST 9 MEDICAL EXAMINER**
**TOXICOLOGY**

Specimen Collected :05/23/2013

Lab Order No: 292301109

Reg Date: 05/23/13

Test Name	Result	Units	Cutoff/Reporting Limits
-----------	--------	-------	-------------------------

**VOLATILE PANEL - VOLP**

SPECIMEN TYPE

**PERIPHERAL BLOOD**

ETHANOL	NONE DETECTED	g/dL	0.020
ACETONE	NONE DETECTED	mg/dL	7.5
METHANOL	NONE DETECTED	mg/dL	15.0
ISOPROPANOL	NONE DETECTED	mg/dL	15.0

Analysis by Gas Chromatography (GC) Headspace Injection

**BLOOD DRUG SCREEN - BDSME**

SPECIMEN TYPE

**RIGHT CHEST BLOOD**

GC/MS

**NICOTINE, NICOTINE METABOLITE, CAFFEINE**

LC/MS/MS

**LC/MS/MS TESTING PERFORMED ON PERIPHERAL BLOOD**
**CAFFEINE, CAFFEINE METABOLITE**
**BLOOD IMMUNOASSAY SCREEN**

SPECIMEN TYPE

**PERIPHERAL BLOOD**

AMPHETAMINES	NEGATIVE	mg/L	0.100
BARBITURATES	NEGATIVE	mg/L	0.100
BENZODIAZEPINES	NEGATIVE	mg/L	0.050
BUPRENORPHINE	NEGATIVE	mg/L	0.001
CANNABINOIDS	NEGATIVE	mg/L	0.050
COCAINE METABOLITE	NEGATIVE	mg/L	0.100
FENTANYL	NEGATIVE	mg/L	0.001
METHADONE	NEGATIVE	mg/L	0.050
OPIATES	NEGATIVE	mg/L	0.050

**Patient:** TODASHEV, IBRAGIM  
**Client Patient ID:** 9-13-623  
**Physician:** UTZ, GARY

**Age:** 27 **Sex:** M  
**Account#:** VX23778  
**Client:** DIST 9 MEDICAL EXAMINER

**TOXICOLOGY**

Specimen Collected :05/23/2013

Lab Order No: 292301109

Reg Date: 05/23/13

Test Name	Result	Units	Cutoff/Reporting Limits
SALICYLATES	NEGATIVE	mg/L	50.0
TRICYCLICS	NEGATIVE	mg/L	0.100

Specimens were intact upon receipt. Chain of custody, specimen security and integrity has been maintained. Testing has been performed as requested

Reviewed by: *Julie Bell* Date: 6/17/13

**FINAL REPORT - THIS COMPLETES REPORTING ON THIS CASE**

TOXICOLOGY\_REPORT

**TODASHEV, IBRAGIM**

ME13-00623

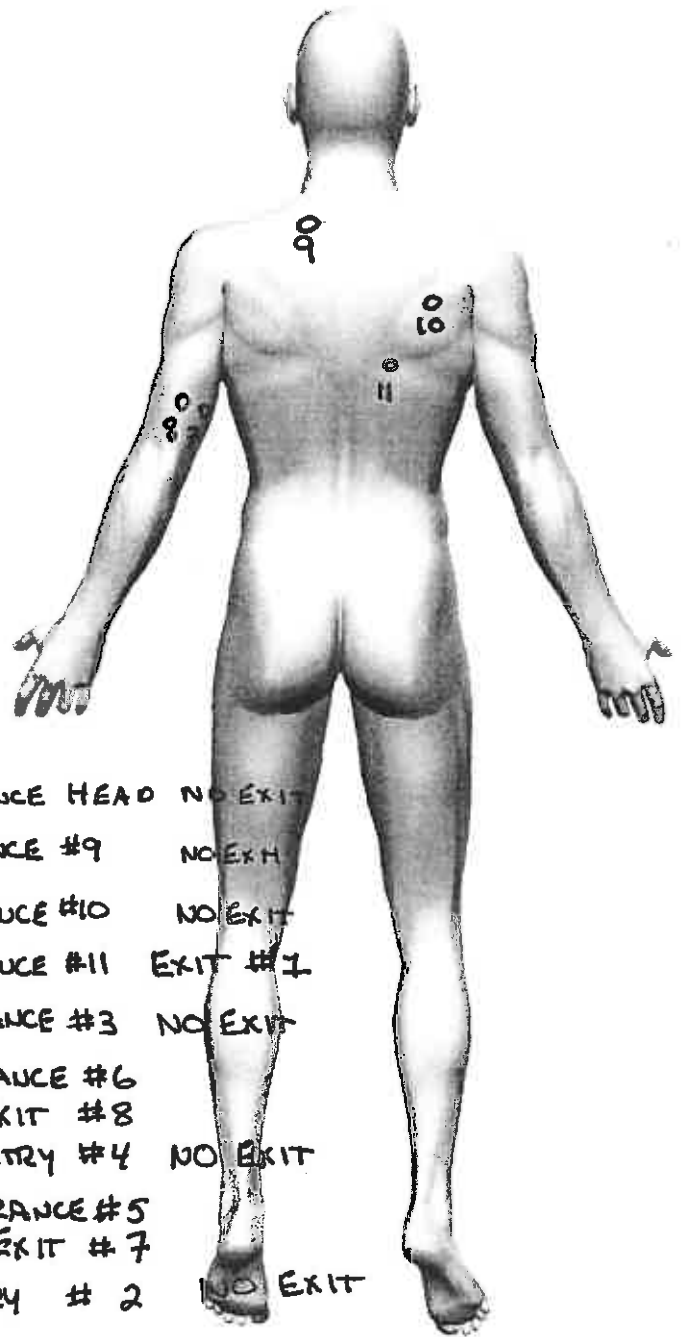
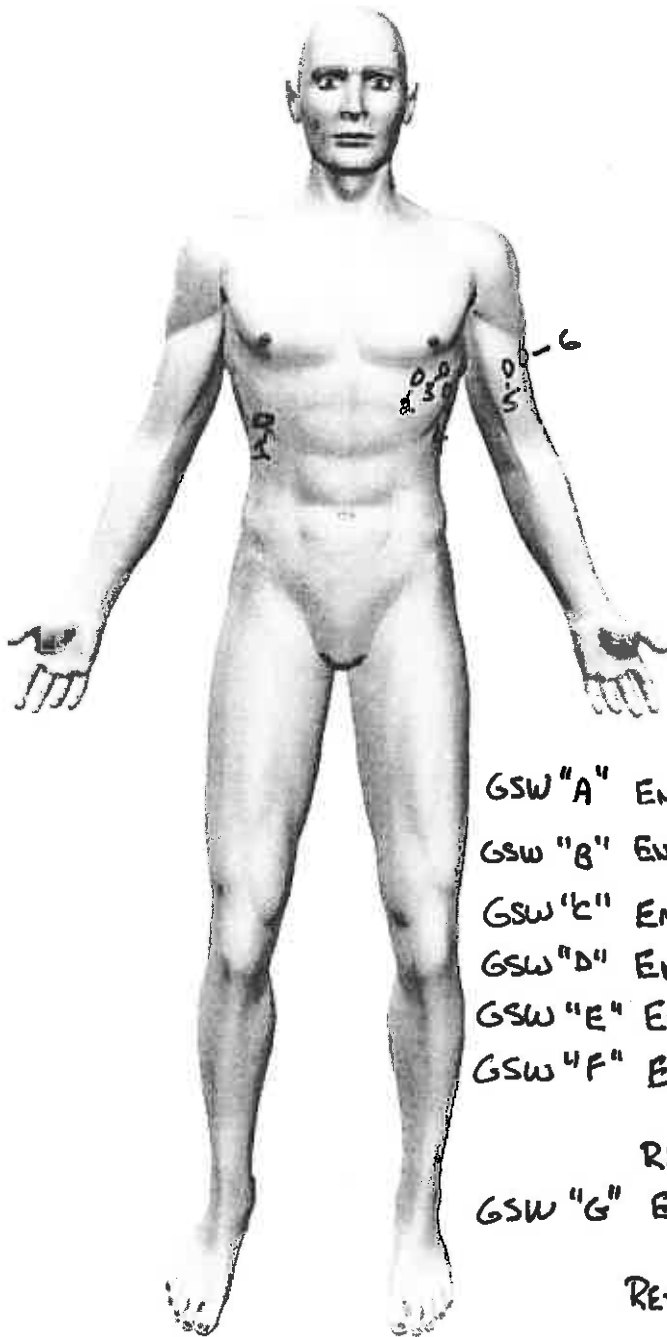
Todashev, Ibragim

27 Years - M

5/22/2013

# INJURY CLARIFICATION 1/2

*Ganguly*



GSW "A" ENTRANCE HEAD NO EXIT  
GSW "B" ENTRANCE #9 NO EXIT  
GSW "C" ENTRANCE #10 NO EXIT  
GSW "D" ENTRANCE #11 EXIT #7  
GSW "E" ENTRANCE #3 NO EXIT  
GSW "F" ENTRANCE #6  
EXIT #8  
RE-ENTRY #4 NO EXIT  
GSW "G" ENTRANCE #5  
EXIT #7  
RE-ENTRY #2 NO EXIT



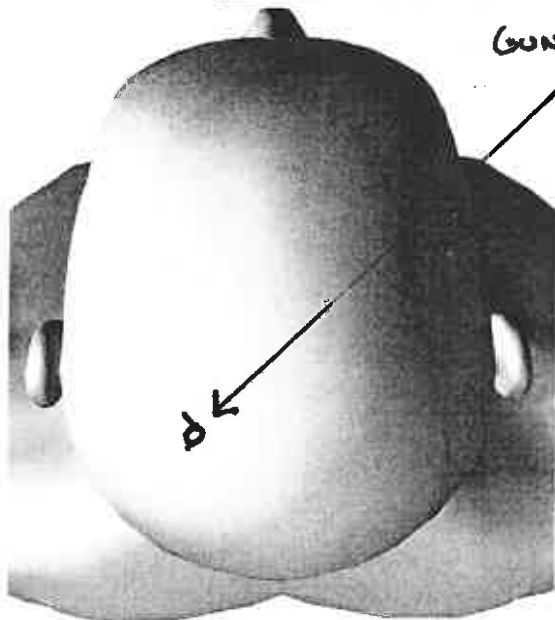
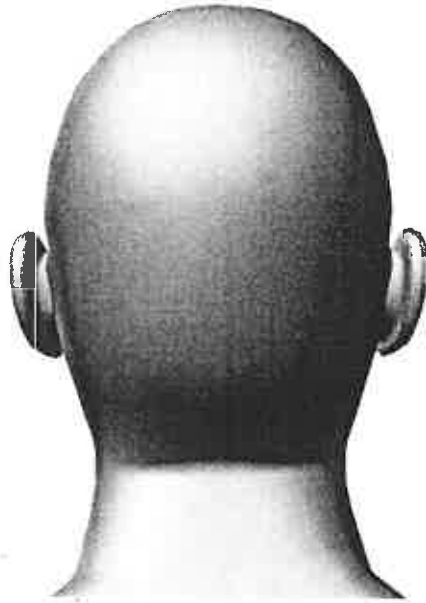
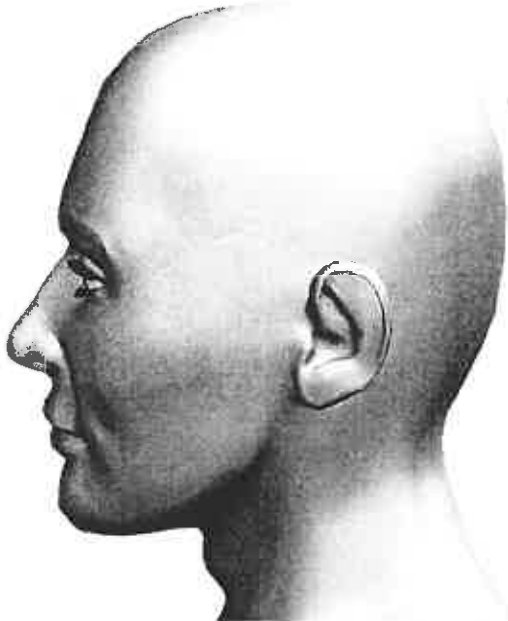
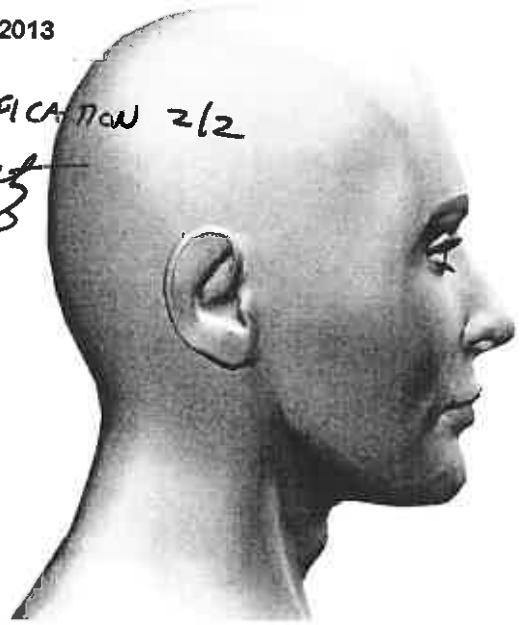
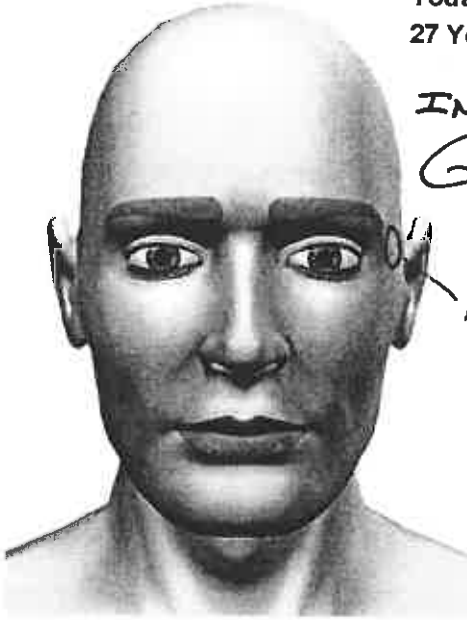
ME13-00623

Todashev, Ibragim

27 Years - M 5/22/2013

INJURY CLARIFICATION 2/2

*Gay*



GUNSHOT ENTRANCE  
(NO EXIT)

